

Diagnostic approaches to equine back problems



Drs. I.B. van Gulik (irisvangulik@gmail.com)

Supervisors: H.J. Bergman (Lingehoeve Diergeneeskunde, Lienden)
G. Bosch (DGP Fac. DGK, Utrecht)



Back pain and dysfunction of the back are common problems in equine practice and are often considered to be a cause of poor performance in athletic horses. The aim of this study was to investigate the value of different diagnostic tools in addition to the clinical exam. Included were nuclear scintigraphy, ultrasonography and radiography. This poster describes the results of radiography of the equine back. A copy of the complete study can be ordered by email.

Comparison of conventional film-screen radiography and computed radiography (CR) of the facet joints of the equine thoracolumbar spine.

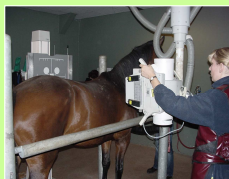

Figure 1. Making radiographs of the equine back. Note the use of a rolling buggy with grid.

Materials and methods

Conventional and digital (CR) radiographs of the facet joints of the thoracolumbar spine region were made of seven Dutch Warmblood horses. The cassettes were placed in a rolling buggy (grid) and high exposures were used (kV 80-125 and mAs 100-250). The radiographs were compared objectively by four experienced observers for diagnostic quality.

Results

- Higher exposure values are necessary for digital radiographs compared to conventional radiographs (table 1).
- The overall diagnostic quality is more consistent in conventional than in digital radiographs.
- Post-processing of digital radiographs is critical, as it is possible to create abnormalities which are in fact artefacts.
- It is more difficult to make a digital radiograph (CR) of good diagnostic quality than it is to make a good conventional radiograph.

	Digital radiograph	Conventional radiograph
Thoracic facet joints	125 kV 160 mAs	80-96 kV 125 mAs
Lumbar facet joints	125 kV 200-250 mAs	85-125 kV 100 mAs

Table 1. Average exposure values necessary for digital and conventional radiographs with the same diagnostic quality of the equine thoracolumbar facet joints.

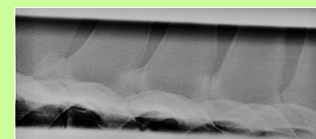


Figure 2. Digital radiograph of equine facet joints.

Conclusion

- With both methods it is possible to make radiographs of the equine facet joint with sufficient diagnostic quality to investigate the thoracolumbar facet joints of horses.

Evaluation of radiation exposure to staff while making radiographs of the equine back.



Figure 3. Measuring the scatter dose with a dosimeter.

Materials and methods

Scatter radiation (μSv) was measured using a dosimeter (Victoreen 450P) at different locations while making radiographs of the equine lumbar facet joints, using 125 KV-250 mAs.

Results

Behind the x-ray tube (the location where the veterinarian was standing) $26 \mu\text{Sv}$ scattered radiation was measured. Behind the lead apron at the same location only $0.56 \mu\text{Sv}$ was measured. On the other side, behind the cassette holder $2.6 \mu\text{Sv}$ was measured.

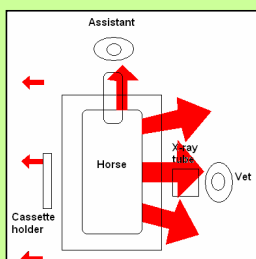


Figure 5. Schematic view of the direction of the scatter radiation (red arrows). The size of the arrows indicates the amount of scatter dose.

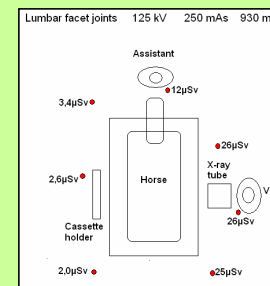


Figure 4. Schematic view of the position of the scatter dose measure points.

Conclusions

- The highest scatter radiation dose was measured at the same side as the x-ray tube (the place of the veterinarian).
- Behind a lead apron the radiation dose was markedly reduced.
- The best place for the assistant to stand is in front of the horse on the same side as the cassette.

Advice: A lead containing screen is the best protection against scattered radiation from back radiographs.

